



PATIENT

Pepper Carle

SPECIES

Canine

BREED

Mix

SEX

Male Neutered

AGE

13 years

WEIGHT

18.3lbs

INTERPRETED BY

Maggie Machen Lamy,
DVM, DACVIM
(Cardiology)

IMAGING PERFORMED BY

Lauren Sikorski, DVM

HOSPITAL NAME

Animal Internal
Medicine

REFERRING VET

Dr. Lauren Sikorski

INVOICE

47634

DATE

4/21/26

PRESENTING CLINICAL SIGNS

History: Respiratory distress. Recent similar episode in FL and received treatment with Furosemide which resolved the clinical signs. Lasix was stopped by the owner due to running out of the medication. Clinical signs reoccurred.

-Abnormal PE/Chem/CBC/UA Results: Crackles. Tachycardic. Increase in RR/RE.

ECHOCARDIOGRAM FINDINGS

2D, m-mode, color flow and doppler imaging is available. The mitral valve is diffusely thickened with prolapse into the left atrial lumen. There is severe eccentric mitral regurgitation present. There is severe left atrial enlargement. From the left apical view, hypoechoic tissue is seen within the left atrial chamber. Suspicion for a mass-like lesion causing bifurcation of blood flow. There is mild left ventricular dilation. Left ventricular systolic function is hyperdynamic. Mild right atrial and ventricular dilation (subjective). Mild thickening of the tricuspid valve with mild TR. The aortic valve appears trileaflet with normal mobility. No significant AI. The main pulmonary artery is normal in diameter. The pulmonic valve is normal in appearance. Flow through the RVOT/PV is normal in velocity. Trace PI. No pericardial/pleural effusion.

CARDIAC CHART

CANINE CARDIAC PARAMETERS	MR VMAX (m/s)	TR VMAX (m/s)	LA/AO (Boon method)	LA/AO (Heart Base; Swe)	FS (%)	EF (%)	EPSS (cm)
NORMAL PARAMETER	4.5-5.5	<2.7	1.3	<1.6	28-40	40-100	<0.6
PATIENT	NM	NM	NM	2.2	51	88	NM
CANINE CARDIAC PARAMETERS	HR (BPM)	AV VMAX (m/s)	PV MAX (m/s)	BODY WEIGHT (kg)	LA 2D short axis Base view (cm)	LVIDd Avg; 2D and m-mode short axis (cm)	LVIDs Avg; 2D and m-mode short axis (cm)
NORMAL PARAMETER	50-100	0.7-1.7	0.7-1.6	BELOW	BELOW	BELOW	BELOW
PATIENT	NM	NM	1.3	8.3	3.4	3.5	1.7
*Normal chamber parameters expressed as a mean value (SD)				3	1.27 (5.3)	2.46 (2.46)	1.36 (5.5)
BODY WEIGHT DEPENDENT PARAMETERS				5	1.40 (4.5)	2.74 (5.2)	1.60 (4.7)
*Note: All measurements based upon multi-modal images and methods. An average value is reported.				10	1.50 (3.8)	3.27 (3.5)	2.06 (3.1)
				15	1.83 (2.0)	3.71 (2.4)	2.43 (2.1)
				20	2.02 (1.9)	4.14 (2.2)	2.80 (2.0)
				25	2.18 (2.4)	4.48 (2.9)	3.10 (2.5)
				30	2.33 (3.3)	4.83 (3.9)	3.39 (3.4)
				35	2.48 (4.3)	5.17 (5.0)	3.69 (4.5)
				40	2.62 (5.2)	5.48 (6.1)	3.96 (5.4)
				50	2.88 (7.1)	6.07 (8.3)	4.46 (7.4)

INTERPRETATION OF THE FINDINGS & FURTHER RECOMMENDATIONS

Chronic degenerative valve disease causing severe mitral and mild tricuspid regurgitation. Severe left atrial enlargement indicates the risk for spontaneous congestive heart failure is elevated. Of additional concern, there is suspicion for a soft tissue lesion within the left atrium. This is suspect, as the lesion is not seen from ancillary views which is somewhat atypical. If confirmed, rules out



PATIENT

Pepper Carle

SPECIES

Canine

BREED

Mix

SEX

Male Neutered

AGE

13 years

WEIGHT

18.3lbs

INTERPRETED BY

Maggie Machen Lamy,
DVM, DACVIM
(Cardiology)

IMAGING PERFORMED BY

Lauren Sikorski, DVM

HOSPITAL NAME

Animal Internal
Medicine

REFERRING VET

Dr. Lauren Sikorski

INVOICE

47634

DATE

4/21/26

would include a mass versus a thrombus; however, further workup is advised. A thoracic CT scan should be considered and/or referral for evaluation by a local Cardiologist. No additional issues are identified.

In light of the clinical signs and severity of disease on echocardiogram, the diagnosis of congestive heart failure (stage C) is supported, and medications are warranted lifelong as below. Monitoring of sleeping respiratory rates will be paramount to screen for congestive heart failure at home. Cough suppression to improve QOL can also be considered (hydrocodone, 0.2-0.4mg/kg up to q4-6h PRN) for any residual mechanical cough in the face of normal sleeping respiratory rates. If able to be stabilized, the average survival time of canine patients with active pulmonary edema is 8-9 months on medications; however, most are able to maintain a good quality of life for that period on medications. Patient will always be at risk for recurrent CHF, development of arrhythmias/LA tear, syncope and/or sudden death in the future.

Omega fatty acid supplementation and mild salt restriction may also be of some long-term benefit. Monitor for acute progression of the cough, labored breathing, exercise intolerance or collapse episodes in the future.

Elective anesthesia is not advised, as there is high risk for complication.

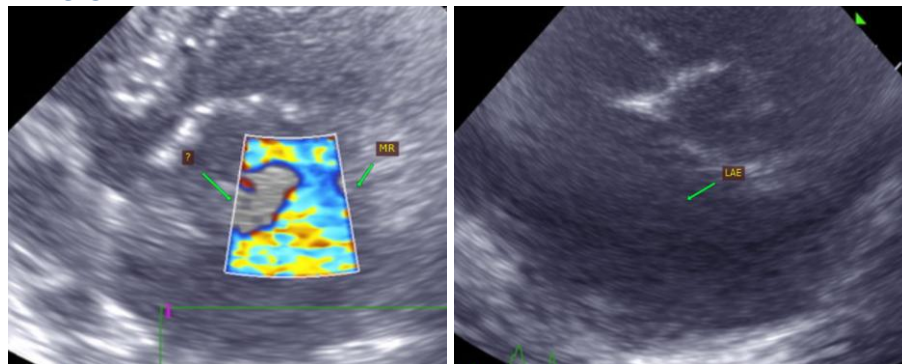
PLAN

Consider advanced imaging as discussed. Institute Pimobendan 0.3mg/kg PO q12h. Institute Furosemide 1-2mg/kg PO q12h. Institute Spironolactone 1-2mg/kg PO q12h.

Monitor renal values and BP in 10-14 days, then every 3-4 months while on diuretics to ensure tolerance of medications. If doing well at home, renal values are reasonable and BP > 130mmHg, administer ACEI 0.5mg/kg PO q12h. Consider hydrocodone if needed for QOL.

Recommend conservative monitoring with a recheck echocardiogram in 6 months, sooner if any development of associated clinical signs occurs in the interim.

IMAGES



The information and recommendations provided are based on the images presented by the referring veterinarian. No evaluation can be communicated regarding pathology that was not



PATIENT

Pepper Carle

SPECIES

Canine

BREED

Mix

SEX

Male Neutered

AGE

13 years

WEIGHT

18.3lbs

INTERPRETED BY

Maggie Machen Lamy,
DVM, DACVIM
(Cardiology)

IMAGING PERFORMED BY

Lauren Sikorski, DVM

HOSPITAL NAME

Animal Internal
Medicine

REFERRING VET

Dr. Lauren Sikorski

INVOICE

47634

DATE

4/21/26

visible in the image/video clips provided.

Thank you for this referral. This report was generated using transcription software, and minor dictation errors may be present. If the clinical or image interpretation does not parallel your findings or if I can be of any further assistance, please contact me.

Maggie Machen Lamy, DVM

Diplomate of the American College of Veterinary Internal Medicine (Cardiology)

info@sonopath.com